



Official Journal of the
Neuroscience Society of Nigeria
(NSN)

ORIGINAL ARTICLE

<https://doi.org/10.47081/njn2018.9.1/004>
ISSN 1116-4182

Effect of Exposure to Mosquito Coil Smoke on Short-Term Memory of Adult Wistar Rats

Mahmood Usman¹, Adebayo Buraimoh², Ahmed-Sherif Isa³, Abubakar S. Adamu¹,
Muhammad M. Muhammad⁴, Haruna D. Umar⁵

¹Department of Human Anatomy, Faculty of Medicine, Ahmadu Bello University, Zaria, Nigeria

²Department of Human Anatomy, Faculty of Medicine, Kaduna State University, Kaduna, Nigeria

³Department of Human Physiology, Faculty of Medicine, Ahmadu Bello University, Zaria, Nigeria

⁴Department of Pharmacology and Therapeutics, Faculty of Pharmaceutical Sciences, Ahmadu Bello University, Zaria, Nigeria

⁵Department of Human Anatomy, Faculty of Basic Medical Sciences, Baze University Abuja, Nigeria

Received: May 2017

Accepted: February 2018

ABSTRACT

Mosquito coil is one of the preferred anti-mosquito products in low income communities because it is cheap and readily available. Burning mosquito coil generates smoke that can repel mosquitoes effectively. However, the smoke contains pollutants that could be detrimental to health. This study was designed to investigate the possible effects that exposure to mosquito coil smoke could have on short-term memory. Twenty-eight (28) adult male Wistar rats were grouped randomly into four of seven animals each. The control, 1 hour, 2 hours and 3 hours of mosquito coil smoke exposure per day. The exposure to the mosquito coil fumes was in a partially ventilated chamber for 21 consecutive days. Novel object recognition test was employed to determine short-term memory in the animals. Brain tissue specimens were collected and fixed in Bouin's fluid and processed for histological examination. The 1 hour, 2 hours and 3 hours smoke exposed showed significant preference for familial objects. The histological examination of the hippocampus showed normal cellular architecture in the control while neuronal degenerations were observed in the experimental groups. Exposure to mosquito coil fumes for 21 days impaired short-term memory in addition to neurodegenerative changes in the hippocampus of adult Wistar rats.

Key words: *Mosquito coil, Short-term memory, Novel object, Hippocampus*

INTRODUCTION

Every year, millions of cases of insect related diseases are recorded, representing a serious threat to global public health. Insect-borne diseases accounted for about 17% of the estimated global burden of these vector-borne diseases (Akunna et al. 2013). Environmental changes together with operational, financial and managerial problems coupled with increasing population mobility and pesticide resistance have contributed to increase in the prevalence of many of such diseases in recent

decades (Akunna et al. 2013; Harsimran and Harsh 2014). Mosquito coil is one of the preferred anti-mosquito products in low income communities because it is cheap, easy to use and readily available. The coils are burned indoors as a common practice in households across Africa, Asia and South America including Nigeria (Garba et al. 2007;

Correspondence: Mahmood Usman, M.Sc., Department of Human Anatomy, Faculty of Medicine, Ahmadu Bello University, P.M.B. 81006, Zaria, Nigeria. Email: mahmoodusman13@gmail.com; +2348032231944

Pauluhn 2006). World Health Organization Pesticide Evaluation Scheme (WHOPES) stated in 1996 that pesticides when exposed to humans are toxic to some degree (WHO 1996). Motor or sensorimotor function dependent learning and memory tasks may be disrupted by pyrethroids which is the major component of mosquito coil at levels well below those that induce serious neurotoxicity (Wolansky and Harrill 2007). Other mosquito repellents that are not pyrethroid based have also been found to cause brain cells degeneration leading to deficit in learning and memory (Abdel-Rahman et al. 2001; Sudakin and Trevathan 2003). Short-term memory is believed to rely mostly on an acoustic code for storing information, and to a lesser extent a visual code (Alberimi 2001).

Despite the fact that mosquito coil smoke has many potential ill health effects, large populations in the developing countries still use mosquito coils in their daily lives (Liu et al. 2003). However, despite the reported inauspicious effects, there is paucity of information on the toxicological consequence of exposure to mosquito coil smoke on short-term memory, thus research is highly pertinent. This study was therefore designed to investigate the possible effects that exposure to mosquito coil smoke could have on short-term memory.

MATERIALS AND METHODS

Test Substance

Rambo mosquito coil manufactured by Gongoni Company limited, 89A Sharada Industrial Estate, Phase III, Kano, Kano State Nigeria was used.

Experimental Protocol

A total number of 28 male Wistar rats were caged and allowed to acclimatize for two weeks. The animals were weighed and randomly grouped into four groups of seven animals each. The control group was exposed only to normal atmospheric air. One group was exposed to mosquito coil smoke for 1 hour per day, another to mosquito coil smoke for 2 hours per day and the third group was exposed to mosquito coil smoke for 3 hours per day in a partially ventilated chamber for the period of twenty-one consecutive days. All experimental procedures described were done according to the Ahmadu Bello University Committee on Animal Use and Care (ABUCAUC) Research Policy (2010) and in compliance with the National Institutes of Health Guide for the care and use of Laboratory Animals (1985).

Behavioural Test

Novel Object Recognition Test

Novel object recognition was employed to test for short-term memory according to the method of Ennaceur and Delacour (1988) and modified by

Moscardo et al. (2012) and Antunes and Biala (2012). The rats were exposed to two familiar objects and allowed to explore these objects for 2 minutes then the animal was removed and one of the objects was placed with a novel object and the animal was taken back in to the cage (Antunes and Biala 2012). If memory was functioning normally, the rats would have spent much of its time exploring the novel object than it did exploring the familiar object. If exploration time for all objects was the same, this was interpreted as a memory deficit. The index for memory was preference score calculated as the time spent exploring the novel object divided by the total time spent exploring both objects, expressed as a percentage. This novel object recognition test was carried out weekly, at the 7th, 14th and 21st day of the exposure.

Animal Sacrifice

Twenty-four hours after the last exposure, the animals were anesthetized using ketamine/diazepam cocktail (5 mg/kg/0.25 mg/kg) and the whole brain harvested and fixed in Bouin's fluid then processed for histological analysis.

Tissue Processing

The fixed brain tissues were removed from the Bouin's fluid and dehydrated using ascending grades of alcohol. The dehydrated tissues were then cleared in two changes chloroform for two hours, the clearing helped in removing opacity from the dehydrated tissues thereby making them transparent. The cleared tissues were then infiltrated by immersion in molten paraffin wax and allowed to solidify. The embedded tissues were blocked in a rectangular block and then sagittal sections were cut using rotary microtome at 5µm per section. The tissue sections were allowed to float in water bath at 300°C to help the spreading of the paraffin ribbons. The clean slides were used to pick the tissue from the warm water bath.

Haematoxylin and Eosin (H and E) staining

The slides with brain sections were left to dry and the methods of haematoxylin and eosin staining technique was carried out by de-waxing the tissue in two changes of xylene for three minutes each, hydrated by passing them through descending grades of alcohol (100%, 95%, 90%, and 70%) for three minutes each, then stained in Harris haematoxylin for ten minutes, and washed in tap water to remove excess stain. The slides were then flooded with acid alcohol for few seconds for differentiation and then washed in tap water again. The slides were then blued in Scott's tap water for five minutes and counter-stained with eosin for three minutes. The sections were rinsed in tap water, and then dehydrated in ascending grades of alcohol, and cleared in xylene. Tissues were then mounted with cover slips

using a mounting media (egg white). Sections photomicrographs were taken using digital camera Amscope (MD 900) fitted to light microscope (Leica Microsystem Inc. Tokyo, Japan).

Statistical Analysis

The results were analyzed using the Statistical Package for Social Sciences (SPSS), version 20 and the results expressed as mean \pm SEM. Statistical significance between means were analyzed using one-way analysis of variance followed by Tukey post-hoc test to see where the significance lies. A p-value \leq 0.05 was considered statistically significant.

RESULTS

Effect of Exposure to Mosquito Coil Smoke on Short-Term Memory Test

The result of the short-term memory test using novel object recognition test as shown in Table 1 recorded lower preference score for novel objects in the 1 hour, 2 hours and 3 hours smoke exposed groups compared with control throughout the experimental period. However, the scores were significantly lower ($p \leq 0.01$) in the second week in 1 hour and 2 hours smoke exposure groups compared with the control. Also, the 2 hours and 3 hours smoke exposed groups were significantly lower ($p \leq 0.02$) in the third week compared with the control.

Table 1: The Effects of Exposure to Mosquito Coil Smoke on Short-Term Memory Following Novel Object Recognition Test

Group	Preference Score (%)		
	Week 1	Week 2	Week 3
Control	61.2 \pm 8.6	73.3 \pm 4.6	75.8 \pm 3.6
1 hour smoke exposure	45.4 \pm 9.8	33.7 \pm 14.7*	50.3 \pm 6.4
2 hours smoke exposure	62.2 \pm 7.9	21.9 \pm 4.0*	28.2 \pm 10.4**
3 hours smoke exposure	38.2 \pm 4.1	46 \pm 4.4	36.1 \pm 11.6**

* Significant different at $P \leq 0.01$ compared to the control. ** Significant different at $P \leq 0.02$ compared to the control.

Histology of the Hippocampus

The results of the histological study of hippocampus using H and E showed cyto-architectural overview of the hippocampus (Figure 1) below at lower magnification with the CA1, CA3 and dentate gyrus regions in the control and the mosquito coil fumes exposed groups. Figure 2 shows the CA3 region of

hippocampus from across the groups at medium magnification, with the control group showing intact pyramidal cells and some intact pyramidal cells in the CA3 regions of the animals exposed to 1 hour daily mosquito coil smoke for 21 days. The 2 hours daily smoke exposed and the 3 hours daily smoke exposed shows pyknotic cells which is an indication of degeneration.

DISCUSSION

After 21 days of exposure to mosquito coil smoke, there were gradual decrease in the exploration time for novel objects (less than 50%) which suggest deficit in short-term memory of the smoke exposed animals (Antunes and Biala 2012), with significant difference recorded in the group exposed to mosquito coil smoke for 1 hour in week 2, group exposed to mosquito coil smoke for 2 hours in weeks 2 and 3 and the group exposed to mosquito coil smoke for 3 hours in week 3 compared with the control.

The animals in the control group showed a minimum of 61.2% preference score for novel objects against the familiar objects, indicating that, exposure to mosquito smoke negatively impact short-term memory. Investigations in humans using functional magnetic resonance imaging have revealed hippocampus to play important role in memory processes, such as novelty detection in either environmental or object this is because hippocampus responded similarly to both forms of novelty as reported by Raphael et al. (2014). This suggests that the degeneration observed in the histological examination of the hippocampus in this study have impacted negatively on the object recognition memory assessed.

Mosquito coil smoke contain many gases and particles like carbon monoxide (CO), carbon dioxide (CO₂), pyro(a)benzene and other hydrocarbons (Abubakar and Hassan 2006). CO is particularly known for its ability to displace oxygen from haemoglobin thereby, exposing the neural cells to hypoxic state which results to necrosis (Dimitri and Agamanolis 2013). Histological examination of the hippocampus of the smoke exposed animals revealed nuclear condensation (pyknosis) in the pyramidal cells. The pyknosis appear to be exposure time dependent, with less assault on the animals exposed to the smoke for 1 hour and more assault on the animals exposed to the smoke for 3 hours. This is as a result of the smoke exposure which lead to arrest of cellular functions and subsequently cellular necrosis.

The mosquito coil smoke release gases and particles that could interfere with the normal cellular processes of energy generation. The first result of energy depletion is failure of sodium and potassium ions pumps, leading to depolarization of the neuronal

membrane, then synaptic function and conductivity ceases (Dimitri and Agamanolis 2013). Depolarization cause neurons to release glutamate into the synaptic cleft which excessively excite the neurons and when the glutamate is in excess, it results in excitotoxicity (Dimitri and Agamanolis

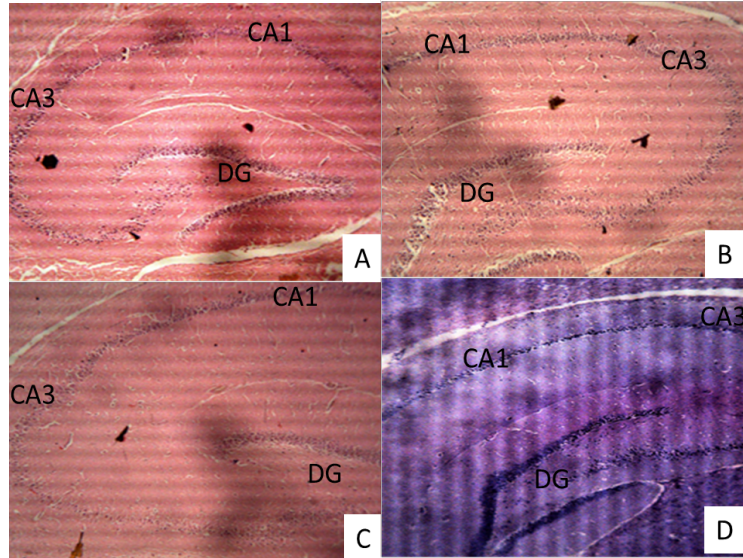


Figure 1: Cross Section of the Hippocampus of Wistar Rats; (A) exposed to ambient air, (B) exposed to 1 hour of mosquito coil smoke for 21 days, (C) exposed to 2 hours of mosquito coil smoke for 21 days and (D) exposed to 3 hours of mosquito coil smoke for 21 days with the CA1, CA3 and Dentate gyrus (DG) regions, ($\times 40$); H & E stain.

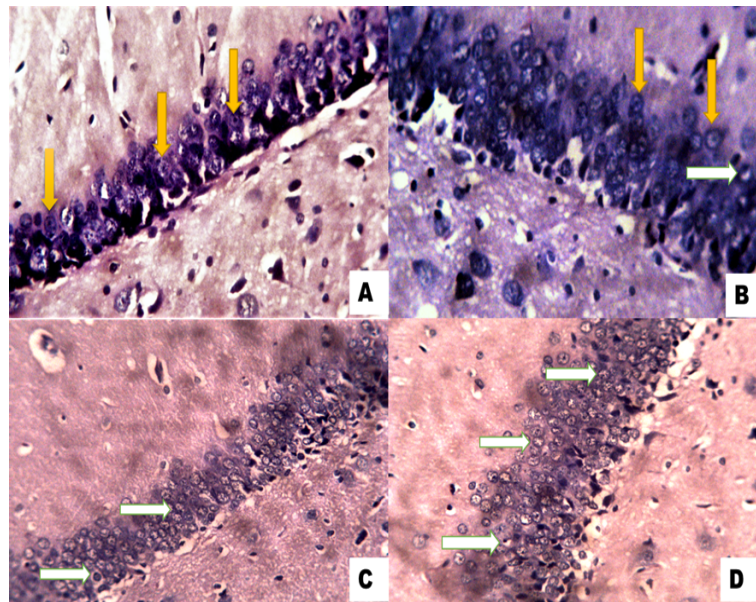


Figure 2: Cross Section of CA3 Regions of Hippocampus; (A) of control animals exposed to fresh air showing pyramidal cells (yellow arrow). (B) Hippocampus of animal exposed to mosquito coil smoke for 1 hour through 21 days with pyramidal cells (yellow arrow) and a degenerating cell (white arrow). (C) Animal exposed to mosquito coil smoke for 2 hours through 21 days with degenerating (pyknotic) cells (white arrow). (D) Animal exposed to mosquito coil smoke for 3 hours through 21 days with more pyknotic cells (white arrow), ($\times 250$); H & E stain.

2013). Since some glutamate receptors are non-selective cation-permeable ion channels, over activation of these channels causes a passive influx of chloride and sodium ions into cells causing cytotoxic oedema and rapid cell death. Additional functional changes like excitotoxicity develop after some days as a result of calcium ion influx into neurons (Dimitri and Agamanolis 2013).

CONCLUSION

The exposure to mosquito coil smoke for the period of 21 days has significantly negative impact on short-term memory. The smoke exposed animals had less than 50% preference score for the novel object against the familiar object which served as an indication of memory deficit. The varying degree of the histopathological changes observed across the mosquito coil smoke exposed groups can be attributed to the smoke polluted environment caused by the mosquito coil smoke.

Conflict of Interest

None declared.

REFERENCES

- Abdel-Rahman, A., Shetty, A. K. and Abou-Donia, M. B. (2001) Subchronic dermal application of N, N-diethyl m-toluamide (DEET) and permethrin to adult rats, alone or in combination, causes diffuse neuronal cell death and cytoskeletal abnormalities in the cerebral cortex and the hippocampus, and Purkinje neuron loss in the cerebellum. *Journal of Experimental Neurology*. 172:153-171.
- Abubakar, M. and Hassan, L. (2006) Toxicological effects of some mosquito coils brands in experimental rats. *The Internet Journal of Toxicology*. 4(1):1-4.
- Akunna, G. G., Saalu, L. C., Ogunlade, B., Ogunmodede, O. S. and Akingbade, A. M. (2013) Anti-fertility role of allethrin based mosquito coil on animal models. *International Journal of Biology, Pharmacy and Allied Sciences*. 2(2):192-207.
- Alberimi, C. M. (2001) Mechanisms of memory stabilization: are consolidation and reconsolidation similar or distinct processes. *Trends in Neuroscience*. 28:51-56.
- Antunes, M. and Biala, G. (2012) The

novel object recognition memory: neurobiology, test procedure, and its modification. *Cognitive Process*. 13:93-110.

Dimitri, P. and Agamanolis, M. D. (2013) Hypoxic-ischemic encephalopathy. *Neuropathology*. 8:26-38.

Ennaceur, A. and Delacour, J. (1988) A new one-trial test for neurobiological studies of memory in rats. 1. Behavioural data. *Behavioural Brain Research*. 31:47-59.

Garba, S. H., Adelaiye, A. B. and Mshelia, L. Y. (2007) Histopathological and biochemical changes in the rats kidney following exposure to a pyrethroid based mosquito coil. *Journal of Applied Sciences Research*. 3(12):1788-1793.

Harsimran, K. G. and Harsh, G. (2014) Pesticides: Environmental impacts and managerial strategies. *Intech Journals*. 1:90-104.

Liu, W., Zhang, J., Hashim, J. H., Jalaludin, J., Hashim, Z. and Goldstein, B. D. (2003) Mosquito coil emissions and health implications. *Environmental Health Perspectives*. 111(12):1454-1460.

Moscardo, E., Salvetti, B., Becchi, S., Bertini, G. and Fabene, P. F. (2012) The novel object recognition test in rodents: Which are the essential methodological aspects? *Proceedings of Measuring Behaviour*. 28(31):476-478.

National Institute of Health (1985) Guide for the care and use of laboratory animals. <https://www.nap.edu>.

Pauluhn J. (2006) Mosquito coil smoke inhalation toxicity. Part I: Validation of test approach and acute inhalation toxicity. *Journal of Applied Toxicology*. 26(3):269.

Raphael, K., Aidan, J. H., Peter, A. B., Christian, F. D. and Neil, B. (2014) Human hippocampal processing of environmental novelty during spatial navigation. *Hippocampus*. 24:740-750.

Sudakin, D. L. and Trevathan, D. R. (2003) DEET: a review and update of safety and risk in the general population, *Journal of Clinical Toxicology*. 41:831-839.

World Health Organization, WHO (1996) Report of the WHO informational Consultation on the evaluation and testing of insecticides, Geneva, 7-11 October 1996. World Health Organization (CTD/WHOPES/IC/96.1).

Wolansky, M. J. and Harrill, J. A. (2007) Neurobehavioral toxicology of pyrethroid insecticides in adult animals: A critical review, *Neurotoxicology Teratology*. 30(2):55-78.